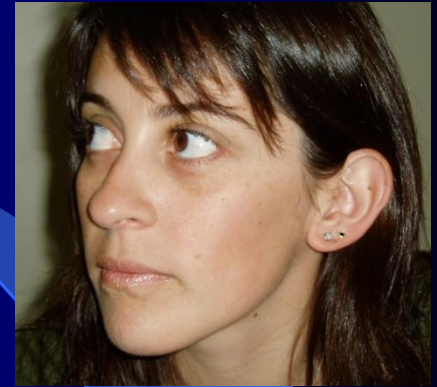


Hypermobile Ehlers-Danlos

Typical Facial Appearance



- Triangular face (pointed jaw).
- Atypical ears: prominent “winged”; small, round and without lobule; lobule attached to the face; Different shapes: kidney shape, “Dumbo” ears, pointed “Mr. Spock” ears, soft ears, bent upper helix, prominent ante helix; question mark shape ears; operated ears.
- Light blue sclera, more noticeable in women.
- Atypical nose: nodule between the bone and the cartilage; deviated nasal septum; operated nose.
- Antimongolic slant



← ————— →
Ref. Bravo JF. Arthritis Rheum 2006; 54 (2): 515-23